

Severe epileptic encephalopathies in children: West and Lennox – Gastaut syndromes

IVONA ŠIJAN, IVANA BOŽIĆ, JAKOV MILIĆ

JOSIP JURAJ STROSSMAYER UNIVERSITY OF OSIJEK, FACULTY OF MEDICINE OSIJEK

DOI: <http://dx.doi.org/10.17486/gyr.3.1022>

SUMMARY: Epileptic encephalopathies are epilepsy syndromes in which the epileptiform abnormalities themselves are believed to contribute to a progressive disturbance in cerebral function. The two most important syndromes in this group are West and Lennox–Gastaut syndromes. West syndrome frequently occurs in the first year of life, in clusters with consequences such as developmental arrest and mental retardation. It characteristically presents with the triad of infantile epileptic spasms, developmental delay and hypsarrhythmia. The treatment is ACTH, prednisolone or valproate. Lennox–Gastaut syndrome typically presents with multiple seizure types, slow spike–wave complexes in the EEG and impaired cognitive function. It is treated with felbamate, lamotrigine, topiramate and rufinamide with poor response to treatment.

KEYWORDS: Epilepsy syndrome; Epileptic encephalopathy; Lennox – Gastaut syndrome; West syndrome

Epilepsy is a condition that affects nearly 50 million people worldwide¹. It can be defined as a brain disorder with recurring and unpredictable episodes of seizures caused by excessive and abnormal synchronous neural activity of the cerebral cortex, which can be induced by cellular or molecular defects in cerebral tissue^{2,3}.

Based on the 2010 report by the International League Against Epilepsy (ILAE), epilepsy syndromes are defined as sets of signs and symptoms that define a unique epilepsy condition. They are classified as idiopathic focal epilepsies of infancy and childhood, familial (autosomal dominant) focal epilepsies, symptomatic (or probably symptomatic) focal epilepsies, idiopathic generalized epilepsies, reflex epilepsies, progressive myoclonus epilepsies, seizures not necessarily requiring a diagnosis of epilepsy and epileptic encephalopathies.

Epileptic encephalopathies are defined as conditions in which the epileptiform abnormalities themselves are believed to contribute to a progressive disturbance in cerebral function. They include early myoclonic encephalopathy, Ohtahara syndrome, West syndrome (Infantile spasms), Dravet syndrome (previously known as severe myoclonic epilepsy in infancy), Myoclonic status in non-progressive encephalopathies, Lennox–Gastaut syndrome, Landau–Kleffner syndrome, and Epilepsy with continuous spike–waves during slow-wave sleep. West and Lennox–Gastaut syndromes are the most recognizable ones in the group because of their frequency and severity⁴. In this review, we will present the most relevant features of these two syndromes.

West syndrome

West syndrome (Infantile spasms; IS; Blitz–Nick–Salaam–Krämpfe, jackknife convulsions) is a serious form of epilepsy that mostly presents in infants and young toddlers. This severe epileptic syndrome was first described in a 1841 Lancet article titled “On a peculiar form of infantile convulsions.” Dr. WJ

West, a British general practitioner at the time, wrote a letter to the editor describing, in minute detail, the symptoms his own son, James Edwin, suffered from. His report is still regarded as a classic. He reported a type of spasms which frequently occurred in the first year of life, appearing in clusters with consequences such as developmental arrest and mental retardation. Unfortunately, dr. West’s letter did not fulfill its intended purpose, which was to find an effective treatment for his son’s condition, since ACTH was identified as the drug of choice a century too late to help young James Edwin^{5, 6, 7}.

The incidence of infantile spasms is between 2 and 3 per 10,000 live births^{8,9}. In approximately 90% of the affected infants the spasms surfaced during the first year, with a peak incidence between 4 and 8 postnatal months^{9,10}. In some cases, infantile spasms are known to affect newborns, but very rarely does the disease have a late onset and occur in older children^{11,12}. The condition is somewhat more frequent in male infants. A family history of infantile spasms exists in 3–6% of the affected children⁹.

In a minor percentage of cases, infantile spasms affect infants who are otherwise healthy, with no identifiable etiological factor and no growth or psychomotor impairment preceding the diagnosis. Such cases are classified as idiopathic or primary forms of infantile spasms and tend to have a better prognosis.^{13,14,15} However, in more than 70% of the affected infants a specific cause can be identified. In these secondary or symptomatic forms of IS, it is enormously important to recognize the underlying disease which led to IS, due to the possibility of introducing an effective specific etiological treatment, therefore influencing the course and outcome of the disease and reducing its consequences.⁷

For this reason, as soon as infantile spasms are diagnosed, the next step should be ordering a full diagnostic workup to investigate if there is a specific cause for this epileptic syndrome. Tuberos sclerosis is one of the underlying diseases commonly identified in infants with infantile spasms, being present

in 7-25% of these infants^{16,17}. Infantile spasms are the first manifestation of disease in more than two-thirds of the infants with tuberous sclerosis, according to some studies^{18,19}. There are also other causes of infantile spasms, for example: focal cortical dysplasias and other cortical development anomalies (usually in the posterior quadrants of the brain), hypoxic-ischemic injury, cystic encephalomalacia, trauma, metabolic diseases, meningitis and encephalitis in newborns, congenital infectious diseases (such as toxoplasmosis, herpes simplex infections and rubella), chromosomal conditions such as Down syndrome and genetic syndromes such as Aicardi's syndrome^{20,21,22,23,24}. A triad characteristic for West syndrome includes infantile epileptic spasms, developmental delay (such as mental retardation) and hypsarrhythmia in the EEG. Before the onset of spasms, development can be normal or delayed, depending on the underlying condition²⁵. The form of the spasms is usually very distinctive: sudden and brief contractions of flexors lead to the flexion of the neck and torso, accompanied by shoulder adduction, arm extension and variable flexion of the lower extremities. These seizures last for about a second and often appear in clusters.

The clinical appearance of the spasms may vary in intensity overtime. For example, in the beginning the spasms may be very subtle and are sometimes even thought to be normal Moro reflexes. But, after some time, they usually become more obvious and easier to diagnose^{7, 26}. The EEG is consistently pathologically altered²⁷. The characteristic interictal EEG finding of hypsarrhythmia, a highly chaotic EEG pattern with high amplitudes, sharp waves and slow waves associated with spikes, is present in two thirds of patients. In the remaining third, a focal surge can be found²⁵. In 2% of the patients with West syndrome the EEG shows no interictal abnormalities. If spasms occur without pathological EEG patterns, the diagnosis of benign infantile myoclonus should be considered²⁸. Moreover, since this epileptic syndrome is often caused by an underlying condition, further investigations have to be done., Neuroradiological imaging such as MRI should be performed. Some studies report that brain MRIs are abnormal in approximately 80% of children with this diagnosis¹⁵. Functional neuroimaging techniques such as PET scans can be performed to identify areas of glucose hypometabolism, which usually correlate with the epileptogenic zone or focal cortical dysplasia. Before deciding on the therapeutic regimen which will be given to the patient, it is crucial to know if there is an underlying condition causing the syndrome and if the condition itself is treatable. If so, the patient should receive specific etiological


therapy. Furthermore, the prognosis and expectations regarding the successful effect of the therapeutic regimen on the patient's development should be defined and explained to the patient's parents in advance.

Therapy goals in the treatment of West syndrome differ from those in other types of seizures. The only way for patients with West syndrome to achieve normal psychomotor and cognitive development is by establishing complete control of seizures, as well as normalization of the interictal EEG pattern. However, it is important to note that more than two-thirds of the affected infants also have an underlying condition, which not only induces the appearance of seizures, but also impairs normal development by itself. In these cases, a normal development is simply impossible to achieve. Keeping this in mind, therapy goals often have to be lowered to just controlling the seizures⁷. The current drugs of choice used for the treatment of infants with West syndrome differ from the therapeutic regimens for other types of seizures. Adrenocorticotropic hormone (ACTH) is the most common firstline therapy given. It has the most evidence of efficacy, reportedly reducing infantile spasms by 50-65%²⁹. Some studies report that high doses of oral prednisolone are equally efficient but less expensive than ACTH^{30,31}. Valproate is another drug used in treatment and seems to be more effective in patients with tuberous sclerosis³². Other treatment strategies are being developed, but there is currently not enough evidence of their efficacy. For example, it seems that a ketogenic diet might lead to a good outcome in 20 to 35% of cases otherwise resistant to therapy³⁰. Moreover, a study showed good therapeutic response to high-dose intravenous immunoglobulines, especially in infants with idiopathic IS, but further research into these regimens is still needed³³. Surgical treatment should be considered for patients with underlying intracranial lesions¹⁰. The prognosis of West syndrome varies from case to case, depending on the etiology of the epilepsy and the therapeutic regimen administered^{34,35}. Most infants have a poor prognosis. Around 15 to 30% of infants with idiopathic West syndrome develop normally with a satisfactory therapeutic response, leading to complete control of seizures. Limited natural history studies report that spontaneous remission occurs in as many as 30% of infants with infantile spasms³⁶. Unfortunately, 20% infants with IS die before the age of 5, while more than 75% of the survivors experience learning difficulties. 50% have seizures that continue into adulthood. I. In one-half of them West syndrome evolves to Lennox-Gastaut syndrome²⁶.





William G. Lennox



Henri Gastaut

Lennox – Gastaut syndrome

Lennox – Gastaut syndrome (LGS) is undoubtedly one of the most important severe generalized epilepsies of early childhood³⁷. The condition was first described by Lennox and Davis in 1950 and then by Gastaut in 1966. It was classified by the International League against Epilepsy Classification Commission in 1989³⁸. LGS is an age-related epileptic encephalopathy, with a peak incidence between the ages of 3 and 5. Onset is usually before the age of 8, although rare cases have also been reported in adolescence^{38, 39}. The syndrome is quite rare, with an annual incidence of 0.2–2.8/10,000 births in European countries⁴⁰. The prevalence rate is in the broad range between 1 and 10% of all childhood epilepsies, which is probably a consequence of unclear diagnostic criteria³⁹.

The etiology of the disorder is heterogeneous. Two major groups can be differentiated^{39, 40}. Approximately 1/4 of cases are considered to be idiopathic, while the remaining 3/4 is symptomatic – most commonly the result of brain injury (i.e. developmental malformations, hypoxic – ischemic injury, infection)^{39, 40}. The age of onset is usually somewhat later in cryptogenic cases⁴⁰.

West's syndrome is present as a predisposing condition in 1/5 of cases⁴¹. The etiology, pathogenesis and pathophysiology of LGS are still largely unknown^{39, 42}. Three factors can be blamed for our incomplete understanding of this subject: lack of an animal model, slow progress in identifying genetic factors and variable pathological substrates^{39, 42}. Lennox–Gastaut syndrome is usually characterized by multiple seizure types, including tonic seizures, atypical absence seizures, tonic or atonic falls („drop attacks“) and frequent non-convulsive status epilepticus; slow spike – wave complexes in the EEG and impaired cognitive function^{37, 38, 43}. Tonic seizures are the type most commonly associated with LGS and they represent a diagnostic criterion, even though they are not always present at onset^{38, 39}. They can vary in severity. Mild ones can only affect movements of eye muscles or contraction of facial muscles with flexion of the neck, but there are also severe attacks that can involve axial muscles or almost the whole body (global tonic attacks³⁹). Atypical absence seizures are associated with a brief lapse in consciousness. They can sometimes be truly challenging to recognize, as they are often very subtle and the patients they occur in often already have deteriorated cognitive function (one of the hallmarks of this syndrome)³⁸. “Drop attacks” or sudden tonic or atonic falls are not diagnostic criteria for LGS, but appear in approximately 50% of patients. Unexpected falls usually follow a myoclonic

jerk and can lead to multiple injuries³⁹. Approximately 65% of patients experience non-convulsive status epilepticus that usually consists of consecutive atypical absence seizures with brief episodes of tonic seizures⁴¹. The classic EEG feature is a slow (≤ 2.5 Hz) spike-and-wave pattern with abnormal background activity. Bursts of generalized fast polyspikes (10 Hz), that usually occur during non-REM sleep and are connected to tonic attacks, are also a diagnostic criteria in the EEG profile^{38, 39, 41}. However, these changes in the EEG are not pathognomonic for the disorder³⁸.

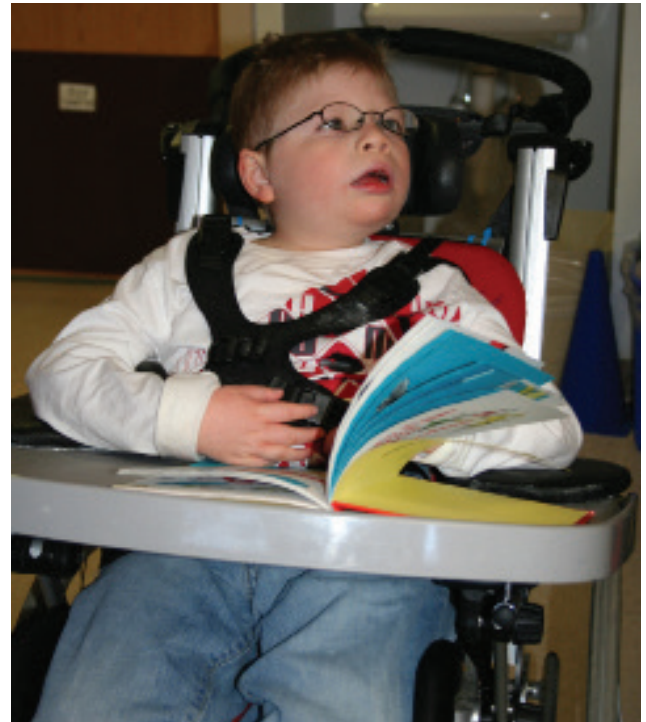Cognitive impairment is present in 20 – 60% of patients at the onset of LGS. The reason for some of the children's developmental delay is a preexisting condition such as West syndrome^{38, 39, 41}. Within 5 years of the onset, 75 – 95% of children develop severe cognitive disabilities^{38, 39}. Psychiatric disorders, such as psychosis, can also occur^{38, 41}.

Another distinguishing trait of LGS is its generally poor response to standard anticonvulsive medication. The various seizure types that can take place in LGS limit treatment possibilities. Felbamate, lamotrigine, topiramate and rufinamide are the only 4 agents that are approved by the U.S. Food and Drug Administration (FDA) for the treatment of LGS. Felbamate, which was the first agent to receive FDA approval, inhibits the glycine N-methyl-d-aspartate (NMDA) receptor and potentiates γ -aminobutyric acid (GABA)-evoked responses. Considering the fact that the side effects of therapy with this agent can be aplastic anemia and hepatic failure, the use of felbamate has been limited to patients unresponsive to other treatment⁴³. Lamotrigine blocks sodium channels, but it is implied that this agent may also have supplementary mechanisms of action such as stabilizing neural membranes and inhibiting the release of excitatory neurotransmitters (glutamate and aspartate)^{40, 43}. Use of lamotrigine has been associated with nystagmus, dizziness and rashes ranging from simple urticaria to serious conditions, including Stevens-Johnson syndrome and toxic epidermal necrolysis. Topiramate modulates sodium channels and reduces GABA uptake. Side effects such as acute glaucoma and oligohidrosis have been reported, but use of this agent has not been connected to any life – threatening events yet⁴⁰. Rufinamide is an orphan drug used in the treatment of LGS. Its mechanism of action is largely unknown, but it is suggested that it limits the activation rate of voltage-gated sodium channels⁴³. Common adverse effect associated with rufinamide include headaches, somnolence, fatigue, tremor and vomiting^{40, 43}. Despite these treatment options, development of optimal therapy for LGS still remains an open question and long – term prognosis is poor for most patients.^{41, 43} The

epilepsy itself tends to ameliorate over time, but seizures always remain present to a certain degree and cognitive deterioration usually becomes more apparent with age⁴¹.

Conclusion

West syndrome and Lennox – Gastaut syndrome are severe epileptic encephalopathies that most commonly affect small children. Their etiopathogenesis is unclear and their response to therapy is poor.



LITERATURE:

1. KWAN P, BRODIE MJ. EARLY IDENTIFICATION OF REFRACTORY EPILEPSY. *N ENGL J MED.* 2000;342(5):314–9.
2. FISHER RS, VAN EMDE BOAS W, BLUME W, ELGER C, GENTON P, LEE P, ET AL. EPILEPTIC SEIZURES AND EPILEPSY: DEFINITIONS PROPOSED BY THE INTERNATIONAL LEAGUE AGAINST EPILEPSY (ILAE) AND THE INTERNATIONAL BUREAU FOR EPILEPSY (IBE). *EPILEPSIA.* 2005;46(4):470–2.
3. TAFAKHORI A, AGHAMOLLAI V, FAGHIHI-KASHANI S, SARRAF P, HABIBI L. EPILEPTIC SYNDROMES : FROM CLINIC TO GENETIC. *IRAN J NEUROL.* 2015;14(1):1–7.
4. ENGEL J. ILAE COMMISSION REPORT A PROPOSED DIAGNOSTIC SCHEME FOR PEOPLE WITH EPILEPTIC SEIZURES AND WITH EPILEPSY : REPORT OF THE ILAE TASK FORCE ON CLASSIFICATION AND TERMINOLOGY. *EPILEPSIA.* 2001;42(6):796–803.
5. WEST WJ: ON A PECULIAR FORM OF INFANTILE CONVULSIONS. *LANCET* 1841, 1:724–725
6. ELING P, RENIER WO, POMPER J, BARAM TZ. THE MYSTERY OF THE DOCTOR'S SON, OR THE RIDDLE OF WEST SYNDROME. *NEUROLOGY.* 2002;58(6):953-955.
7. SHIELDS, W. D. (2006). INFANTILE SPASMS: LITTLE SEIZURES, BIG CONSEQUENCES. *EPILEPSY CURRENTS*, 6(3), 63–69. [HTTP://DOI.ORG/10.1111/J.1535-7511.2006.00100.X](http://doi.org/10.1111/j.1535-7511.2006.00100.x)
8. RIIKONEN R. EPIDEMIOLOGICAL DATA OF WEST SYNDROME IN FINLAND. *BRAIN DEV* 2001;23:539–541.
9. HRACHOVY RA, FROST JD: SEVERE ENCEPHALOPATHIC EPILEPSY IN INFANTS: INFANTILE SPASMS (WEST SYNDROME).IN *PEDIATRIC EPILEPSY: DIAGNOSIS AND THERAPY.* EDITED BY PELLOCK JM, BOURGEOIS BF, DODSON WE, NORDLI DR JR, SANKAR R. NEW YORK, NY: DEMOS MEDICAL PUBLISHING; 2008:249–268
10. ZUPANC. INFANTILE SPASMS. *CURRENT OPINION IN NEUROLOGY.*1995;8(2): 139–144.
- 11.WONG M, TREVATHAN E. INFANTILE SPASMS. *PEDIATRNEUROL* 2001;24: 89–98.
12. BEDNAREK N,MOTTE J, SOUFFLET C, PLOUINP,DULAC O. EVIDENCE OF LATE-ONSET INFANTILE SPASMS. *EPILEPSIA* 1998;39:55–60
13. VIGEVANO F, FUSCO L, CUSMAI R, ET AL.: THE IDIOPATHIC FORM OF WEST SYNDROME. *EPILEPSIA* 1993, 34:743–746.
14. DULAC O, FEINGOLD J, PLOUIN P, ET AL.: GENETIC PREDISPOSITION TO WEST SYNDROME. *EPILEPSIA* 1993, 34:732–737.
15. SINGER WD, RABE EF, HALLER JS. THE EFFECT OF ACTH THERAPY UPON INFANTILE SPASMS. *J PEDIATR* 1980; 96(3 PT 1):485–489.
16. PAMPLIGLIONE G, MOYNAHAN EJ: THE TUBEROUS SCLEROSIS SYNDROME: CLINICAL AND EEG STUDIES IN 100 CHILDREN. *J NEUROLNEUROSURGPSYCHIATR* 1976, 39:666–673.
17. MATSUMOTO A, WATANABE K, NEGORO T, ET AL.: INFANTILE SPASM: ETIOLOGICAL FACTORS, CLINICAL ASPECTS, AND LONG-TERM PROGNOSIS IN 200 CASES. *EUR J PEDIATR* 1981, 135:239–244.
18. SANKAR R, SHIN D, MAZARATI AM, ET AL.: ONTOGENY OFSELF-SUSTAINING STATUS EPILEPTICUS. *DEV NEUROSCI* 1999,21:345–351.
19. HUNT A: TUBEROUS SCLEROSIS: A SURVEY OF 97 CASES.*DEV MED CHILD NEUROL* 1983, 25:346–349.
20. OHTAKI E, YAMAGUSHI Y, SHIOTSUKI Y, ET AL.: A CASE OF INFANTILE SPASM DUE TO HERPES SIMPLEX TYPE VIRUS ENCEPHALITIS. *NO TO HATTATSU* 1987, 19:502–506.
21. JELLINGER K: NEUROPATHOLOGICAL ASPECTS OF INFANTILE SPASM. *BRAIN DEV* 1987, 9:349–357.
22. MEENCKE HJ, GERHARD C: MORPHOLOGICAL ASPECTS OF AETIOLOGY AND THE COURSE OF INFANTILE SPASMS (WEST-SYNDROME). *NEUROPEDIATRICS* 1985, 16:59–66.
23. RUGGIERI V, CARABALLO R, FEJERMAN N: INTRACRANIAL TUMORS AND WEST SYNDROME. *PEDIATR NEUROL.* 1989;5:327–329
24. SCHEFFER IE, BERKOVIC SF, CAPOVILLA G, CONNOLLY MB, GUILHOTO L, HIRSCH E, ET AL. THE ORGANIZATION OF THE EPILEPSIES: REPORT OF THE ILAE COMMISSION ON CLASSIFICATION AND TERMINOLOGY INGRID. 2012.
25. RUGG-GUNN F, SMALLS J, EDITORS. *EPILEPSY 2013 FROM MEMBRANES TO MANKIND: A PRACTICAL GUIDE TO EPILEPSY.* 14TH EDITI. CHALFONT ST PETER: EPILEPSY SOCIETY; 2013.
26. SHORVON S, PERUCCA E, ENGEL J, EDITORS. *THE TREATMENT OF EPILEPSY.* 3RD ED. WILEY-BLACKWELL; 2009.
27. KELLAWAY P, FROST JD, HRACHOVY RA. INFANTILE SPASMS. IN: *ANTIPILEPTIC DRUG THERAPY IN PEDIATRICS.* NEW YORK: RAVEN PRESS, 1983: 115– 136.
28. LOMBROSO CT, FEJERMAN N. BENIGN MYOCLONUS OF EARLY INFANCY. *ANN NEUROL.* 1977; 1: 138–143.
29. SNEAD OC: OTHER ANTIPILEPTIC DRUGS: ADRENOCORTICOTROPHIC HORMONE (ACTH): IN: *ANTIPILEPTIC DRUGS.* LEVY RH, MATTSON RH, MELDRUM BS (EDS), RAVEN



PRESS, PRESS, NEW YORK, USA (1989):905-912.

30. KOSOFF EH, HARTMAN AL, RUBENSTEIN JE, VINING EP. HIGH-DOSE ORAL PREDNISOLONE FOR INFANTILE SPASMS: AN EFFECTIVE AND LESS EXPENSIVE ALTERNATIVE TO ACTH. *EPILEPSY BEHAV.* 2009; 14:674–676.
31. COPPOLA A, BETANCOURTH D, GALANOPOULOU AS. MODELING NEW THERAPIES FOR INFANTILE SPASMS. 2011;51(SUPPL 3):27–33.
32. CHIRON C, DUMAS C, JAMBAQUE I, MUMFORD J, DULAC O. RANDOMIZED TRIAL COMPARING VIGABATRIN AND HYDROCORTISONE IN INFANTILE SPASMS DUE TO TUBEROUS SCLEROSIS. *EPILEPSY RES.* 1997; 26:389–395.
33. ARIIZUMI M, BABA K, HIBIO S, SHIHHARA H, MICHIIHIRO N, OGAWA K, OKUBO O. IMMUNOGLOBULIN THERAPY IN THE WEST SYNDROME. *BRAIN DEV.* 1987;9:422–425
34. KOSOFF EH, PYZIK PL, MCGROGAN JR, VINING EP, FREEMAN JM. EFFICACY OF THE KETOGENIC DIET FOR INFANTILE SPASMS. *PEDIATRICS.* 2002;109:780–783. HRACHOVYR. WEST'S SYNDROME (INFANTILE SPASM). CLINICAL DESCRIPTION AND DIAGNOSIS. *ADVEXPMED BIOL.* 2002;497:33–50
35. SINGER WD, HALLER JS, SULLIVAN LR, WOLPERT S, MILLS C, RABE EF. THE VALUE OF NEURORADIOLOGY IN INFANTILE SPASMS. *J PEDIATR.* 1982; 100: 47–50
36. HRACHOVY RA, GLAZE DG, FROST JD JR. A RETROSPECTIVE STUDY OF SPONTANEOUS REMISSION AND LONG-TERM OUTCOME IN PATIENTS WITH INFANTILE SPASMS. *EPILEPSIA.* 1991;32:212–214
37. DULAC O, N'GUYEN T. THE LENNOX-GASTAUT SYNDROME. *EPILEPSIA.* 1993;34, S7–S17.
38. ARZIMANOGLU A, FRENCH J, BLUME WT, CROSS JH, ERNST JP, FEUCHT M, ET AL. LENNOX-GASTAUT SYNDROME: A CONSENSUS APPROACH ON DIAGNOSIS, ASSESSMENT, MANAGEMENT, AND TRIAL METHODOLOGY. *THE LANCET NEUROLOGY.* 2009. P. 82–93.
39. CAMFIELD PR. DEFINITION AND NATURAL HISTORY OF LENNOX-GASTAUT SYNDROME. *EPILEPSIA.* 2011;52: 3–9.
40. VAN RIJCKEVORSEL K. TREATMENT OF LENNOX-GASTAUT SYNDROME: OVERVIEW AND RECENT FINDINGS. *NEUROPSYCHIATR DIS TREAT.* 2008;4:1001–19.
41. HANCOCK EC, CROSS HHJ. TREATMENT OF LENNOX-GASTAUT SYNDROME. *COCHRANE DATABASE OF SYSTEMATIC REVIEWS.* 2009.
42. BLUME WT. PATHOGENESIS OF LENNOX-GASTAUT SYNDROME: CONSIDERATIONS AND HYPOTHESES. *EPILEPTIC DISORDERS.* 2001; 3: 183–196.
43. MONTOURIS GD. RATIONAL APPROACH TO TREATMENT OPTIONS FOR LENNOX-GASTAUT SYNDROME. *EPILEPSIA.* 2011;52:10–20.

Teške epileptične encefalopatije u dječjoj dobi: Sindromi West i Lennox – Gastaut

SAŽETAK: Epileptične su encefalopatije epileptični sindromi kod kojih se vjeruje da su same epileptiformne abnormalnosti čimbenik nastanka progresivnih poteškoća u cerebralnoj funkciji. Dva najznačajnija sindroma u ovoj skupini su sindromi West i Lennox–Gastaut. Westov sindrom se učestalo pojavljuje u prvoj godini života s posljedicama kao što su zastoj u razvoju i mentalna retardacija. Trijas karakterističan za ovaj sindrom čine infantilni epileptični spazmi, zastoj u razvoju i hipsaritmija. Uobičajeno se liječi s ACTH, prednizolonom ili valproatom. Za Lennox–Gastautov su sindrom tipični različiti oblici konvulzija, spori šiljak-val kompleksi u EEG-u i oštećena kognitivna funkcija. Liječi se felbamatom, lamotriginom, topiramatom i rufinamidom uz slab odgovor na liječenje.

KLJUČNE RIJEČI: Epileptični sindrom; epileptična encefalopatija; Lennox-Gastaut sindrom; West sindrom